

Gigantic Pulmonary Arteriovenous Malformation Presenting as Recurrent Lung Infection

BRAJESH KUMAR KUNWAR¹, FARAH INGLE², ATUL INGLE³, CHANDRASEKHAR TULAGSERI⁴

(CC) BY-NC-ND

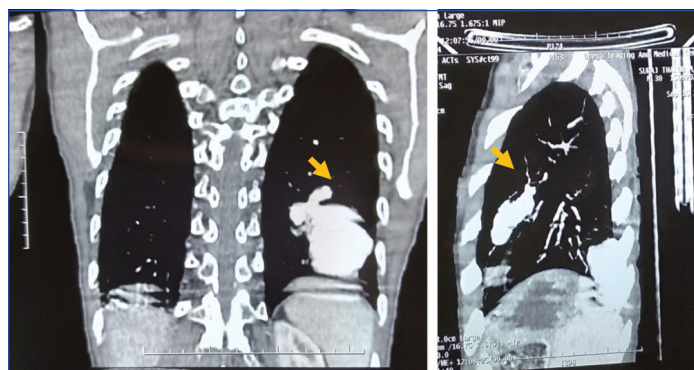
ABSTRACT

The abnormal connection between pulmonary arterial and venous circulation is known as Pulmonary Arteriovenous Malformation (PAVM). It was first described by Churton in 1897. The presentation varies from incidental findings to shortness of breath, haemoptysis, chest pain, syncope and cyanosis. Patients with hereditary haemorrhagic telangiectasia are prone to develop PAVM. PAVMs are quite rare, the frequency ranges from 2-3 per 1,00,000 population. Treatment options include surgical intervention and embolisation, the former is now used seldom. The surgical intervention is more invasive than the percutaneous intervention procedure also known as embolotherapy or embolisation. In the present case, authors encountered a rare case of a 30-year-old male presented with giant PAVM with 13 mm diameter (60.65×35.32 mm in dimensions), where patient presented with fever since two months and vomiting. Considering his symptoms, he was initially suspected as Coronavirus-2019 (COVID-19) positive. However, his Reverse Transcription-Polymerase Chain Reaction (RT-PCR) test was reported negative. It was decided to treat him with vascular plug embolisation. A 16 mm Amplatzer vascular plug II was deployed in such a way that it does not occlude the lower branches of Left Pulmonary Artery (LPA). After deploying the vascular plug, the patient was stable and tolerated the procedure well. He was discharged after two days of observation considering his haemodynamic stability.

Keywords: Angiography, Embolisation, Percutaneous, Pulmonary

CASE REPORT

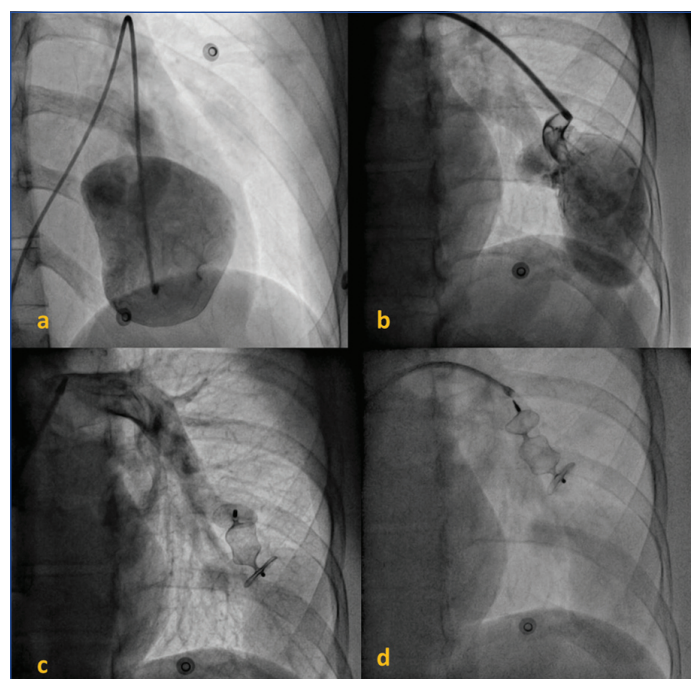
A 30-years-old male presented to the Department of Cardiology with complaints of fever since two months along with vomiting, and altered sensorium. He had intermittent fever with no diurnal variation since two months. He was afebrile for seven days prior to admission in our hospital. One and a half month earlier, he had visited another facility where he was diagnosed with lobar pneumonia with Pulmonary Arteriovenous Malformation (PAVM). His arterial blood pressure was 80/100 mmHg and his blood oxygen level was 96% on 2 L oxygen. His RT-PCR test for COVID-19 was done and results were negative. Patient chest Computed Tomography (CT) revealed PAVM in left lower lobe [Table/Fig-1] with 13 mm diameter (60.65×35.32 mm in dimensions). He self-declared no telangiectasia of skin. He was advised for peripheral embolisation with vascular plug and provided consent for the same.



[Table/Fig-1]: Computed Tomography (CT) of chest revealing giant pulmonary arteriovenous malformation.

Selective angiogram of LPA showed large arterial connection from descending branch of LPA to large Arteriovenous Malformation (AVM) [Table/Fig-2a,b]. Angiogram of right pulmonary artery showed three small insignificant AVMs. The 6F diagnostic catheter was replaced with a 7F 90 cm sheath in the right femoral vein. The sheath was parked in the neck of the AVM. After confirming the

sheath in the neck of the AVM by multiple check shoots, a 16 mm Amplatzer vascular plug II was deployed [Table/Fig-2c]. The plug was deployed in such a way that it does not occlude the lower branches of LPA. Angiogram showed correctly positioned vascular plug. Repeat angiogram five minutes after the procedure showed almost complete closure of AVM [Table/Fig-2d]. He was haemodynamically stable during the procedure. He was kept under observation for two days postprocedure and was discharged on third day in stable condition. Upon discharge, he was prescribed antibiotics, antacids along with other salt and protein supplements. Patient was advised for regular follow-up and was asked to report immediately to Emergency



[Table/Fig-2]: (a) and (b) showing the pulmonary arteriovenous malformation 13 mm in diameter (c) deploying 16 mm Amplatzer Vascular Plug II and (d) final angiogram 5 minutes postprocedure showed total closure of arteriovenous malformation.

Department if fever, severe pain, swelling at operated site, oozing, bleeding, rashes or any other symptoms occurred. He was living normal life after six months follow-up.

DISCUSSION

The abnormal connection between pulmonary arterial and venous circulation bypassing the capillary bed is known as PAVM [1]. In most of the cases, it is usually a congenital (80%) condition, but can also be acquired (20%). The PAVM was first described by Churton in 1897 [2]. Patients with PAVM usually also have family history of haemorrhagic telangiectasia [3]. The presentation varies from incidental findings to shortness of breath, haemoptysis, chest pain, syncope and cyanosis. There are many clinical conditions, which have similar signs and symptoms. Until the advent of percutaneous intervention procedure, surgery was the only treatment approach for PAVMs [4,5]. CT scan is usually considered as a standard diagnosis tool for PAVM, however, pulmonary angiography should be used during embolisation treatment [6]. In the present case of a 30-year-old male presented with history of fever since two months and was already diagnosed with pneumonia and a giant PAVM. He was later treated with percutaneous intervention.

A 30-year-old male presented to the facility in COVID-19 era with typical symptoms of COVID-19; fever. Thus, it was initially suspected him of COVID-19 positive and were advised for RT-PCR. However, on further inquiry, his history revealed lobar pneumonia with PAVM. As CT scan is more sensitive than a chest X-ray authors decided to do a chest CT scan. The PAVM are quite rare, the frequency ranges from 2-3 per 1,00,000 population [7]. As per reports, female are almost twice more prone to be affected by PAVM than males, the ratio varies from 1:1.5 to 1.8 in male and female, respectively [8].

Surgical intervention was the only available treatment option until introduction of percutaneous interventional procedures also known as embolotherapy or embolisation [9]. However, the scenario has changed completely since first successful percutaneous embolisation reported in 1978 by Taylor BG et al., [10]. In the present times, surgical interventions are performed seldom as embolotherapy with coils is safe and efficacious. Surgical treatment requires thoracotomy with lung lobectomy, which increases mortality and morbidity in the patients. Device embolisation being a minimally invasive intervention, the patient can recover fully in 1-2 days of hospitalisation and immediate mobilisation can be possible. The risk associated with intervention in experienced hands is minimal [11]. Thus, in the present case, we chose device embolisation to treat the patient. Vascular plug occlusion has several advantages like easy release and complete occlusion can be done with a single plug. Additionally, the risk of device migration is also less with vascular plug. PAVMs can be present as singular (42-74%) or multiple form

[12]. In present case, a single large PAVM was observed in left lower lobe, and multiple PAVMs were observed in right lobe, but were too small in size. PAVMs are seen majorly in patients with hereditary haemorrhagic telangiectasia [5]. However, in the present case, patient reported no such condition. The telangiectasia usually starts appearing in second or third decade of life [13,14]. Despite patient being 30-year-old, there was no visible telangiectasia of skin.

CONCLUSION(S)

Multiple options exist for treatment of PAVM, however considering the size of PAVM and poor general condition of patient with history of pneumonia in recent times, surgical treatments would have been risky. Hence, vascular plug closure was planned and done successfully. Defining the exact anatomy and localising the feeding vessel is the most important step. Knowing the merits and demerits of different embolising agents (coils, Polyvinyl Alcohol (PVA) particles, devices) helps in successfully completing case of high complexity PAVM thus avoiding surgery.

REFERENCES

- [1] Anabtawi I, Ellison R. Maldevelopment of the pulmonary veins and pulmonary arteriovenous aneurysms. *Am Surg.* 1964;30:770-73.
- [2] Kritharis A, Al-Samkari H, Kuter DJ. Hereditary hemorrhagic telangiectasia: Diagnosis and management from the hematologist's perspective. *Haematologica.* 2018;103(9):1433.
- [3] Gossage JR, Kanj G. Pulmonary arteriovenous malformations: A state of the art review. *Am J Respir Crit Care Med.* 1998;158(2):643-61.
- [4] Zeebregts C, Nijveld A, Lam J, Van Oort A, Lacquet L. Surgical treatment of a fistula between the right pulmonary artery and the left atrium: Presentation of two cases and review of literature. *European Journal of Cardio-Thoracic Surgery.* 1997;11(6):1056-61.
- [5] Krishnamoorthy K, Rao S. Pulmonary artery to left atrial fistula. *Eur J Cardiothorac Surg.* 2001;20(5):1052-53.
- [6] Gill S, Roddie M, Shovlin C, Jackson J. Pulmonary arteriovenous malformations and their mimics. *Clin Radiol.* 2015;70(1):96-110.
- [7] Jha AK, Sunder A. An unusual case of pulmonary arterio-venous fistula (PAVF). *J Family Med Prim Care.* 2019;8(10):3408.
- [8] Sluiter-Eringa H, Orie N, Sluiter H. Pulmonary arteriovenous fistula: Diagnosis and prognosis in noncomplainant patients. *Am Rev Respir Dis.* 1969;100(2):177-88.
- [9] Khanra D, Razi M, Tiwari P, Soni S, Thakur R. Successful occlusion of a large pulmonary arterio-venous fistula with Amplatzer septal occluder in a 16-year-old cyanotic boy. *J Cardiol Cases.* 2020;21(6):242-45.
- [10] Taylor BG, Cockerill EM, Manfredi F, Klatte EC. Therapeutic embolisation of the pulmonary artery in pulmonary arteriovenous fistula. *Am J Med.* 1978;64 (2):360-65.
- [11] Hsu CCT, Kwan GN, Thompson SA, Evans-Barns H, van Driel ML. Embolisation for pulmonary arteriovenous malformation. *Cochrane Database Syst Rev.* 2012;(8).
- [12] Vidjak V, Štula I, Matijević F, Kavr L, Milić HS, Blašković D. Embolisation of pulmonary arteriovenous malformations-Case series. *Pol J Radiol.* 2018;83:e326.
- [13] White Jr R, Lynch-Nyhan A, Terry P, Buescher PC, Farmlitt E, Charnas L, et al. Pulmonary arteriovenous malformations: Techniques and long-term outcome of embolotherapy. *Radiology.* 1988;169(3):663-69.
- [14] Dutton J, Jackson J, Hughes J, Whyte M, Peters A, Ussov W, et al. Pulmonary arteriovenous malformations: Results of treatment with coil embolisation in 53 patients. *AJR: American Journal of Roentgenology.* 1995;165(5):1119-25.

PARTICULARS OF CONTRIBUTORS:

1. Senior Interventional Cardiologist, Head and Director of Catheterization Laboratory, Department of Cardiology, Fortis Hospital, Navi Mumbai, Maharashtra, India.
2. Senior Physician, Department of Cardiology, Fortis Hospital, Navi Mumbai, Maharashtra, India.
3. Senior Nephrologist, Department of Nephrology, Fortis Hospital, Navi Mumbai, Maharashtra, India.
4. Senior Intensivist, Department of Intensive Care, Fortis Hospital, Navi Mumbai, Maharashtra, India.

NAME, ADDRESS, E-MAIL ID OF THE CORRESPONDING AUTHOR:

Dr. Brajesh Kumar Kunwar,
Senior Interventional Cardiologist, Head and Director of Catheterization Laboratory,
Department of Cardiology, Fortis Hospital, Navi Mumbai, Maharashtra, India.
E-mail: Kunwar_brajesh@yahoo.com

AUTHOR DECLARATION:

- Financial or Other Competing Interests: None
- Was informed consent obtained from the subjects involved in the study? Yes
- For any images presented appropriate consent has been obtained from the subjects. NA

PLAGIARISM CHECKING METHODS: [Jain H et al.]

- Plagiarism X-checker: Mar 24, 2021
- Manual Googling: May 24, 2021
- iThenticate Software: Jun 10, 2021 (8%)

ETYMOLOGY: Author Origin

Date of Submission: **Mar 22, 2021**
Date of Peer Review: **Apr 15, 2021**
Date of Acceptance: **May 25, 2021**
Date of Publishing: **Jul 01, 2021**